

Herb formula enhances treatment of impotent patients after penile venous stripping: a randomised clinical trials

C.-H. Hsieh^{1,2}, H.-C. Tsai³, G.-L. Hsu^{3,4}, C.-C. Chen⁴ & C.-Y. Hsu⁴

1 Department of Urology, Taipei Tzuchi Hospital, The Buddhist Tzuchi Medical Foundation, New Taipei City, Taiwan;

2 School of Medicine, Buddhist Tzu Chi University, Hualien, Taiwan;

3 Department of Urology, College of Medicine, National Taiwan University Hospital, Taipei City, Taiwan;

4 Microsurgical Potency Reconstruction and Research Center, Hsu's Andrology, Taipei City, Taiwan

Keywords

Erectile dysfunction—herb formula—penile venous stripping—phosphodiesterase-5 inhibitor—synergic effect

Correspondence

Geng-Long Hsu, MD, Microsurgical Potency Reconstruction and Research Center, Hsu's Andrology and Urology Department of National Taiwan University Hospital, 3F 88, Wen-Hu Street Nei-Hu Dt. 114, Taipei, Taiwan.

Tel.: +886 2 87526087;

Fax: +886 2 87975207;

E-mails: genglonghsu@gmail.com; glhsu@ha.mc.ntu.edu.tw

Accepted: October 10, 2015

doi: 10.1111/and.12508

Summary

Herbs have been regarded as aphrodisiacs in treating impotence for many centuries despite little true scientific evidence. Our latest refined penile venous stripping (PVS) technique is effective in treating impotence, although this procedure remains controversial. A synergic effect of PVS and oral herbs was confirmed in our practice but lacked rigorous scientific proof. The objective of this report was to review our experience with this combination. From August 2010 to May 2014, 263 males underwent PVS. Among these, 67 unsatisfied men chose additional salvage therapy and were randomly assigned to oral herbs ($n = 35$) or placebo treatment ($n = 32$) which replaced herb eventually. All were evaluated with the international index of erectile function (IIEF-5) scoring and our dual pharmaco-cavernosography. The pre-op IIEF-5 score for the herb group was 9.7 ± 3.7 , post-operative 13.9 ± 3.3 and post-herb 19.6 ± 3.4 , while the control group scores were as follows: pre-op 9.3 ± 4.1 , post-op 14.5 ± 3.6 , post-placebo 15.1 ± 3.5 and post-herb 19.9 ± 3.2 . Although there was no significant difference between the two groups pre-operatively, post-operatively and post-herb, a statistically significant difference was found post-salvage therapy (19.6 ± 3.4 versus 15.1 ± 3.6 , $P < 0.001$). It appears that the combination of oral herbs and PVS treatment provides an enhanced outcome to impotent patients refractory to medicine and unsatisfied with PVS monotherapy alone.

Introduction

In a comparative penile anatomy study, an os penis of the animal and the distal ligament of the human male are consistently found to be homologous (Hsu *et al.*, 2005). The rigid body os penis found in selected animal species (dog, whale, etc.) has evolved into a hydraulic system of the human penis, in which the os analogue is the distal ligament. Given the anatomical location and histology of these two structures, many consider this to be potential evidence of the evolutionary process (Hosken & Stockley, 2004; Simmons & Jones, 2007). Interestingly, if we had retained our os penis, the incidence of ED, defined as the consistent inability to achieve and maintain an erect penis satisfactory for intercourse, likely would have been lower, but conceal ability of the erect penis would be socially more challenging (Kaminetsky, 2008). Not surprisingly, the pursuit of penile rigidity

and pleasure is an endless issue (Sandroni, 2001; Ang *et al.*, 2004; Neychev & Mitev, 2005). Many animal and plant products have long been regarded as aphrodisiacs, such as tiger penis, deer antlers, oyster, ginkgo, ginseng and maca among others (Cohen & Bartlik, 1998; Gonzales *et al.*, 2002, 2003; Murphy & Lee, 2002). Herbal products have been regarded as an aphrodisiac in treating impotence for centuries despite little scientific support (Bonnard, 1999). This trend may be changing as options other than phosphodiesterase-5 (PDE-5) inhibitors appear to be evolving. Reports of long-term efficacy issues with PDE-5 inhibitors and their adverse effects remain limiting to many (Nachtsheim, 1998; Morrison, 2000; FDA & Social Media, 2014).

Although penile venous ligation was first described in treating ED in 1902 (Wooten, 1902), its many modified methods (partial excision included) were subsequently abandoned by most medical communities after

experimenting for over one century (Berardinucci *et al.*, 1996; Montague *et al.*, 2005). Nonetheless, we have refined our anatomy-based penile venous stripping (PVS) since 1986 (Tsai *et al.*, 1988; Chen *et al.*, 2005; Hsu *et al.*, 2010a). It has been developed in tandem with the advances of the penile tunical (Hsu *et al.*, 1992) and venous-related anatomy (Hsu *et al.*, 2003; Hsieh *et al.*, 2012) culminating in the latest PVS method which gained US PTO patent in 2012 (Hsu, 2012). Our most recent methods minimise tissue damage by forgoing the use of commonly used techniques such as the suction apparatus and electrocautery (Polk *et al.*, 2001). All procedures are performed on a true outpatient basis under an acupuncture-assisted pure local anaesthesia (Hsu *et al.*, 2013). Our encouraging post-operative outcome along with negligible morbidity and complications has led to a high degree of patient interest (Molodysky *et al.*, 2013).

Using modern biotechnology for plant extraction (Gupta *et al.*, 2012), a novel herb formula free from the side effects of current pharmacotherapy for ED has been sought after for many years. While a synergic effect of PVS and oral herbs was noted in our practice, a formal investigation of this effect has not been published previously. Herein, we would like to report our clinical experience in order to evaluate this potential synergistic effect.

Materials and methods

From August 2010 to May 2014, 263 males underwent the latest version of PVS (Hsu, 2012) for treating impo-

tence resulting from veno-occlusive dysfunction (VOD) based on the new insight of penile anatomy (Fig. 1). Patients included were either nonresponders to PDE-5 inhibitor ($n = 217$) or intolerant of the ($n = 46$) drug's adverse effects pre-operatively. All patients signed informed consent and were investigated under a multiple disciplinary diagnostic approach including our dual pharmaco-cavernosography in which the first set of cavernosograms (Fig. 2a, b) was made immediately before a 20 µg prostaglandin E1 (PGE-1) intracavernous injection (ICI) measuring cavernous artery flow was performed. The diagnosis of VOD was documented via a second set of pharmaco-cavernosograms (Fig. 2c). Patients excluded from participation in this investigation were those with untreated chronic systemic diseases, diabetes mellitus, gout, hypertension, chronic liver disease, renal failure, hormonal insufficiency, and surgery or traumatic erectile dysfunction. All were assessed with the abridged five-item version of the international index of erectile function (IIEF-5) scores and cavernosography when necessary (Fig. 2d–f). Among these, 67 men were nonresponders to PDE-5 inhibitors and unsatisfied with PVS alone at a minimum of 6 months post-operatively. They were randomly allocated to a herb ($n = 35$) and control group ($n = 32$). Subsequently, they were prescribed a once-daily capsule with herb extract or placebo with flour for one month respectively. The control group had the placebo replaced by herb formula the following month. A complete blood count (CBC) and biochemistry profile were obtained before and after this oral treatment.

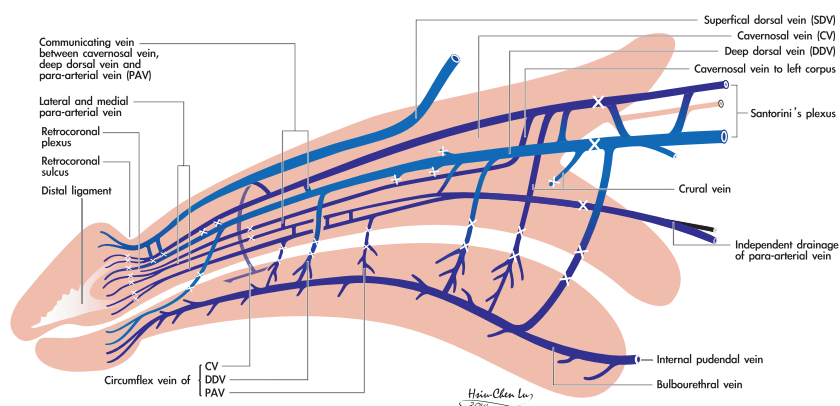


Fig. 1 Schematic illustration of penile venous anatomy in lateral aspect. This is for the blueprint of penile venous stripping (PVS) in this study. It demonstrates the new insight into erection-related vein in the human penis. In between the tunica albuginea and Buck's fascia, there is one deep dorsal vein (DDV), a couple of cavernosal veins (CVs) and two pairs of para-arterial veins (PAVs), in contrast to conventional one – just one single DDV. DDV is consistently in the median position and receives the blood of sinusoids of glans penis and the emissary veins from the corpora cavernosa (CC) and of the circumflex vein from the corpus spongiosum (CS). It is flanked by a pair of CVs which are specifically responsible to drain sinusoidal blood from right and left corpus cavernosum respectively. Bilaterally each dorsal artery is sandwiched by its corresponding medial and lateral PAVs respectively. All veins are distributed along the entire length of corpora cavernosa and also responsible for the blood drainage from the sinusoids of the glans penis, CS and CC. In our experience, a total of 76–132 ligature sites are required to finish the PVS.

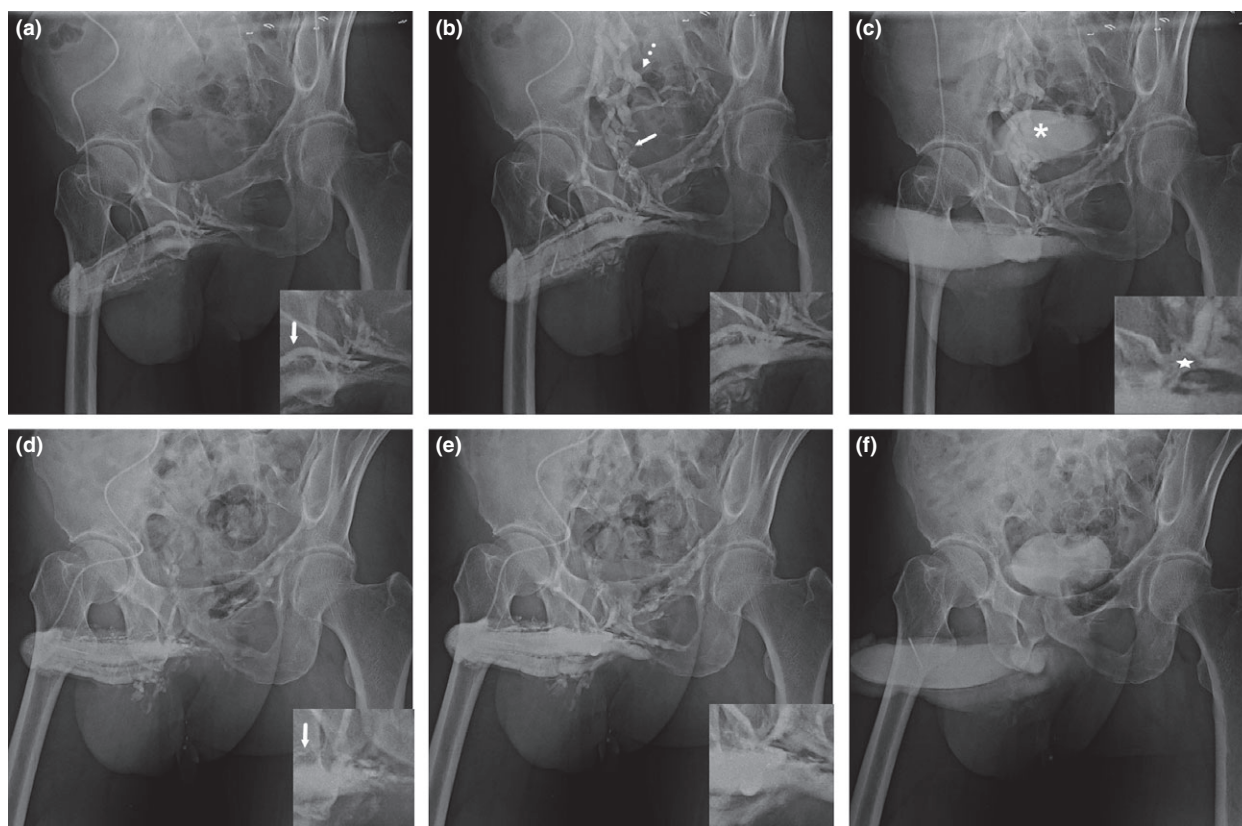


Fig. 2 A representative dual pharmaco-cavernosogram. (a) Immediately after intracavernous injection of 16 ml contrast medium fluid at the speed of 80 ml min^{-1} , one of the first set pre-operative films discloses the deep dorsal vein, rail-like parallel cavernosal veins (inserted) and the entire glans penis, and the corpora cavernosa to internal pudendal veins (arrow in panel (b)) which is continued to the internal iliac vein (dotted arrow in panel (b)). (b) A later phase film shows the above veins and even distribution within the corpora cavernosa, in particular the distensible penile crus after an injection of 30 ml contrast medium. (c) A veno-occlusive dysfunction was documented via a demonstration of a bunch of leakage veins (arrow) in a second set of the dual pharmaco-cavernosography although the intracavernosal pressure was high enough to push the penis into a rigid erection. The urinary bladder (asterisk) was filled because the fluid injected 30 min earlier was secreted by kidney. This subject was subsequently resorted to penile venous stripping (PVS). (d) A follow-up cavernosography was performed because PVS failed to satisfy this patent although an IIEF-5 was increased from 10/25 to 19/25, which denoted a significant improvement. It was a good contract compared to Panel (a). Note that those erection-related veins were stripped out. (e) A later film confirmed an acceptable PVS and consequently it was easier to attain an intracorporeal fluid retention. It was for comparison with that in panel (b). (f) This film was obtained at 5 min after the 60 ml contrast medium fluid was consumed without PGE-1 intracavernous injection which was cautioned against post-PVS.

An IIEF-5 score was obtained and the side effects recorded. A positive response was defined as an increment of IIEF-5 for at least three points.

Penile vein stripping

Under acupuncture-assisted pure local anaesthesia on an ambulatory basis, a circumcision was first performed to thoroughly strip the deep dorsal vein (DDV), cavernosal veins (CVs) and para-arterial veins using a 6-0 nylon suture for ligation (cross marks in Fig. 1). The trunk of DDV and CVs was served as a guide for a pull-through manoeuvre along the Buck's fascia from the retrocoronal

level to the penile base. A longitudinal pubic incision was made to pass underneath the trunk of DDV and CVs in order to continue the stripping procedure which was meticulously managed as proximal as possible until the level of the infrapubic angle was encountered. In our experience, a total of 76–132 ligature sites were needed to complete the procedure. The wound was closed with 5-0 catgut, while the penis was stretched as much as possible by an assistant's hand. Post-operative cavernosograms were used to ascertain the completeness of venous removal. Finally, a compression dressing was placed to encircle the penile shaft, which was left in place for 1 week post-operatively. Patients were routinely followed

up every 6 months post-operatively. Follow-up cavernosography was used in those who were not satisfied with this PVS (Fig. 2d–f).

Oral herb formula and placebo capsule

This herb formula was composed of seven ingredients derived from five commonly used formulas in Chinese traditional medicine. They are *Astragalus membranaceus* 100 mg, *Lepidium meyenii* Walp. (maca) 18 mg, *Ophiocordyceps sinensis* 5 mg, *Panax quiquefolium* (American ginseng) 100 mg, *Piper nigrum* (black pepper) 100 mg, *Rhodiola rosea* 100 mg and *Serpentes cnidium monnieri* 100 mg. 5 g powder was extracted from 10 Kg dried maca root (AB SCIEX Triple Quad™ 3500 System Redefined Simplified Mass Spec; AB SCIEX, Framingham, MA, USA). A final 423 mg capsule was formed (Fig. 3a). A similarly formed 423 mg flour placebo was also encoded (Fig. 3b).

Statistical analysis

Statistical analysis of the data was carried out by the Student *t*-test, paired *t*-test and Wilcoxon signed-rank test whenever appropriate, and a value of $P < 0.05$ was defined as representing a significant difference.

Results

To provide a comprehensive overview, Table 1 summarises the general data of the 67 patients all of whom were nonresponders to PDE-5 inhibitors. The age distribution was 29–67 years (average 45.6 ± 5.8) and 31–68 years (average 46.5 ± 5.9) in the herb and control group respectively. In the herb group, the IIEF-5 scores were as follows: pre-operative, 9.7 ± 3.7 ; post-operative, 13.9 ± 3.3 ; and post-herb, 19.6 ± 3.4 . In contrast in the placebo group, the results showed pre-operative IIEF-5

scores of 9.3 ± 4.1 , post-operative 14.5 ± 3.6 , post-placebo 15.1 ± 3.6 and post-herb 19.9 ± 3.2 . A positive response was attained by 31 patients in the herb group, three patients in the control group and 30 men in the crossover study. Pre-operatively, there were seven and six PDE-5 inhibitor non-responders who reported the drug's intolerable side effects in the herb and control groups, respectively. In the herb group, one patient complained of visual disturbance, two patients reported facial flushing




Fig. 3 Photographs of herb formula and placebo capsule. (a) A total of 423 mg was encoded in a capsule. The ingredients included *Astragalus membranaceus* 100 mg, *Lepidium meyenii* Walp. (maca) 18 mg, *Ophiocordyceps sinensis* 5 mg, *Panax quiquefolium* (American ginseng) 100 mg, *Piper nigrum* (black pepper) 100 mg, *Rhodiola rosea* 100 mg and *Serpentes cnidium monnieri* 100 mg. (b) A twinlike placebo capsule was made of 423 mg flour. It was intentionally designed for this experiment. Could a difference be observed by its appearance? Note that two nicks and one nick were made in panel (a) and (b) respectively in this photography. A capsule was denuded and put on top in panel (a) and (b) respectively.

Table 1 Demography of 67 patients who took herb or placebo for the treatment of impotence

Grouping	Patient		IIEF-5 score				ICI ^b
	No.	Age	Pre-op	Post-op	Post-herb	Implant	
Herb group	35	29–67	9.7 ± 3.7	13.9 ± 3.3	19.6 ± 3.4	2	0
Control group (Cross study)	32	31–68	9.3 ± 4.1	14.5 ± 3.6	15.1 ± 3.5 19.9 ± 3.2^c	1	2
Total	67						2
<i>P</i> -value ^a		0.54	0.65	0.5	Both < 0.001	0.101	0.02

Pre-op: pre-operative; post-op: post-operative; IIEF, international index of erectile function.

^aUnivariate comparisons were performed using the Student *t*-test, paired *t*-test for parameters with continuous values and the Wilcoxon signed-rank test with discontinuous parameters.

^bICI denotes intracavernosal injection of prostaglandin E1.

^cThis was the IIEF-5 score of patients in control group who were exposed to herb the following month.

and three patients experienced mild stomach burning sensation which was temporary. Surprisingly, five men reported a significant improvement in nocturia frequency and three men demonstrated improved hypertension.

Two patients underwent AMS spectra penile implant in the herb group, and only one patient chose to have implant surgery in the control group in late 2014. ICI therapy was used weekly in two men in the control group. Neither CBC nor biochemistry profile parameters changed in this study (Fig. 4).

Although there was no significant difference between the two groups pre-operatively (9.7 ± 3.7 versus 9.3 ± 4.1 , $P = 0.65$), post-operatively (13.9 ± 3.3 versus 14.5 ± 3.6 , $P = 0.50$) and post-herb (19.6 ± 3.4 versus 19.9 ± 3.2 , $P = 0.68$), there was a statistically significant difference in terms of IIEF-5 score (19.4 ± 3.4 versus 15.1 ± 3.5 , $P < 0.001$; 19.9 ± 3.2 versus 15.1 ± 3.5 , $P < 0.001$) and positive response rate ($61/67 = 90.0\%$ versus $3/32 = 9.4\%$, $P < 0.0001$) for oral herb treatment. Post-operative cavernosograms consistently showed that intracorporeal fluid retention was more likely.

Discussion

Impotence is found in all societies and afflicts a great portion of the population regardless of the social status and age (Melman & Gingell, 1999; McKay, 2004). The development and subsequent approval of PDE-5 inhibitors

transformed medical practice in the field of ED. While these agents are helpful for most, at least 30% of those affected remain refractory or unable to take these agents. Perhaps, this is best demonstrated by the rising numbers of men undergoing surgical therapies for ED. Penile prosthesis implantation has increased from 17,540 in 2000 to 22,420 in 2009 in the United States (Montague, 2011). Therefore, we believe a need remains for careful evaluation of a natural treatment for impotence using herbs, although advanced extracting methods for herbs from natural products are available worldwide, but are costly.

In this study, all patients had pre-operatively failed the PDE-5 inhibitor treatment and reported some intolerable adverse effects such as headache, palpitation, flushing, nasal obstruction, dry mouth and visual disturbance. They claimed waiver to PDE-5 inhibitors, which prevents us from prescribing sildenafil for synergism (Wen *et al.*, 2005). Excitingly, in this study this herb formula was almost free from those adverse effects and only transient symptoms such as visual disturbance, facial flushing and mild stomach burning were reported. In addition, there was no change in CBC and biochemistry parameters. Similar to extensive study on the mechanism of PDE-5 inhibitor agent (Doh *et al.*, 2002), albeit there are many research articles on herbs (Brown *et al.*, 2001; Hadley, 2005; Do *et al.*, 2013), further mechanism research is warranted for adding ingredients in this herb formula.

Veno-occlusive dysfunction (venous incompetence or leakage) remains a highly prevalent aetiology within impotent patients (Fuchs *et al.*, 1989) and occurs in those whose impotence may be primarily arteriogenic resulting from heavy cigarette smoking (Elhanbly *et al.*, 2004). Clinically refined PVS benefits most impotent males (Hsu *et al.*, 2010b). This belief was further supported after a couple of recent studies on fresh and defrosted human cadavers, while a fully rigid erection was readily attainable and maintainable after penile erection-related veins were thoroughly stripped and ligated closest to the tunica albuginea (Hsieh *et al.*, 2005; Hsu *et al.*, 2012). An easier intracorporeal fluid retention was reported by those who were not satisfied with PVS alone. In 2006, a stunning priapism occurred in a 56-year-old patient who underwent PVS a couple of years ago after ICI of $10 \mu\text{g}$ PGE-1. We currently caution against the usage of $20 \mu\text{g}$ PGE-1 in post-PVS patients either for pharmaco-cavernosography or for ICI therapy. An initial trial dosage of $5 \mu\text{g}$ PGE-1 is recommended in post-operative PVS patients. We handled two cases in this study. In contrast, there was a negligible side effect of herb in this study. Furthermore, some men even report an improvement in nocturia frequency and other chronic diseases. Further research is warranted.

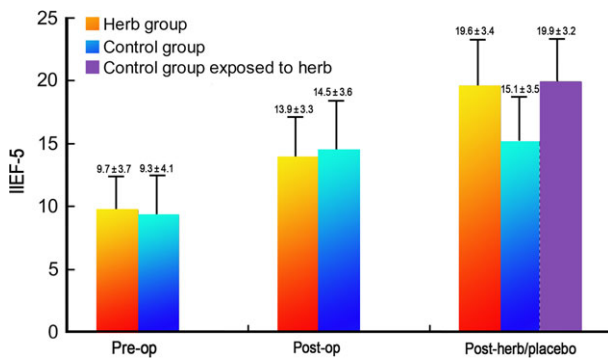


Fig. 4 Illustration in bar showing international index of erectile function (IIEF) changes in this study. In herb and control groups, the IIEF-5 scores were as follows: pre-operative 9.7 ± 3.7 versus 9.3 ± 4.1 , post-operative 13.9 ± 3.3 versus 14.5 ± 3.6 , post-herb 19.6 ± 3.4 versus 15.1 ± 3.5 versus 19.9 ± 3.2 respectively. Although there was no significant difference between the two groups pre-operatively (9.7 ± 3.7 versus 9.3 ± 4.1 , $P = 0.65$), post-operatively (13.9 ± 3.3 versus 14.5 ± 3.6 , $P = 0.50$) and post-herb (19.6 ± 3.4 versus 19.9 ± 3.2 , $P = 0.68$), there was a statistically significant difference in terms of IIEF-5 score (19.4 ± 3.4 versus 15.1 ± 3.5 , $P < 0.001$; 19.9 ± 3.2 versus 15.1 ± 3.5 , $P < 0.001$) after oral herb treatment or placebo treatment.

Conclusion

Although a longer term follow-up and a larger sample size will be required before a definitive statement can be made, this report demonstrates the minimal morbidity of adding herbal approaches onto surgical therapy for treating refractory patients with VOD. It appears that oral herb and PVS treatment may provide a solution to impotent patients who are refractory to medicine and unsatisfied with PVS alone.

Acknowledgements

We would like to thank Professor Gerald Brock for his English editing, along with Ms Hsiu-Chen Lu, Han-Ju Chen Margaret Su-Lan Tang and Venus Ying-Hui Chen, and to thank them for their preparations of illustration and photographs for this manuscript.

References

- Ang HH, Lee KL, Kiyoshi M (2004) Sexual arousal in sexually sluggish old male rats after oral administration of *Eurycoma longifolia* Jack. *J Basic Clin Physiol Pharmacol* 15:303–309.
- Berardinucci D, Morales A, Heaton JP, Fenemore J, Bloom S (1996) Surgical treatment of penile veno-occlusive dysfunction: is it justified? *Urology* 47:88–92.
- Bonnard M (1999) *The Viagra Alternative: The Complete Guide to Overcoming Erectile Dysfunction Naturally*. Inner Traditions/Bear & Company, Rochester.
- Brown GA, Vukovich MD, Martini ER, Kohut ML, Franke WD, Jackson DA, King DS (2001) Effects of androstenedione-herbal supplementation on serum sex hormone concentrations in 30- to 59-year-old men. *Int J Vitam Nutr Res* 71:293–301.
- Chen SC, Hsieh CH, Hsu GL, Wang CJ, Wen HS, Ling PY, Huang HM, Tseng GF (2005) The progression of the penile vein: could it be recurrent? *J Androl* 26:56–63.
- Cohen AJ, Bartlik B (1998) Ginkgo biloba for antidepressant-induced sexual dysfunction. *J Sex Marital Ther* 24:139–143.
- Do J, Choi S, Choi J, Hyun JS (2013) Effects and mechanism of action of a *Tribulus terrestris* extract on penile erection. *Korean J Urol* 54:183–188.
- Doh H, Shin CY, Son M, Ko JI, Yoo M, Kim SH, Kim WB (2002) Mechanism of erectogenic effect of the selective phosphodiesterase type 5 inhibitor, DA-8159. *Arch Pharm Res* 25:873–878.
- Elhanbly S, Abdel-Gaber S, Fathy H, El-Bayoumi Y, Wald M, Niederberger CS (2004) Erectile dysfunction in smoker: a penile dynamic and vascular study. *J Androl* 25:991–995.
- FDA & Social Media (2014) *Viagra vs. Levitra vs. Cialis, a side effect and effectiveness comparison for a male patient aged 52*. eHealthMe (Study ID: 4083426).
- Fuchs AM, Mehninger CM, Rajfer J (1989) Anatomy of penile venous drainage in potent and impotent men during cavernosography. *J Urol* 141:1353–1356.
- Gonzales GF, Córdova A, Vega K, Chung A, Villena A, Góñez C, Castillo S (2002) Effect of *Lepidium meyenii* (maca) on sexual desire and its absent relationship with serum testosterone levels in adult healthy men. *Andrologia* 34:367–372.
- Gonzales GF, Córdova A, Vega K, Chung A, Villena A, Góñez C (2003) Effect of *Lepidium meyenii* (maca), a root with aphrodisiac and fertility-enhancing properties on serum reproductive hormone levels in adult healthy men. *J Endocrinol* 176:163–168.
- Gupta AM, Naraniwal M, Kothati V (2012) Modern extraction methods for preparation of bioactive plant extracts. *Int J Appl Nat Sci* 1:8–26.
- Hadley ME (2005) Discovery that a melanocortin regulates sexual functions in male and female humans. *Peptides* 26:1687–1689.
- Hosken DJ, Stockley P (2004) Sexual selection and genital evolution. *Trends Ecol Evol* 19:87–93.
- Hsieh CH, Wang CJ, Hsu GL, Chen SC, Ling PY, Wang T, Fong TH, Tseng GF (2005) Penile veins play a pivotal role in erection: the hemodynamic evidence. *Int J Androl* 28:88–92.
- Hsieh CH, Liu SP, Hsu GL, Chen HS, Molodysky E, Chen YH, Yu HJ (2012) Advances in our understanding of mammalian penile evolution, human penile anatomy and human erection physiology: clinical implications for physicians and surgeons. *Med Sci Monit* 18:RA118–RA125.
- Hsu GL (2012) Physiological approach to penile venous stripping surgical procedure for patients with erectile dysfunction. <http://patft.uspto.gov/netacgi/nph-Parser?Sect1=PTO1&Sect2=HITOFF&d=PALL&p=1&u=%2Fnethtml%2FPTO%2Fsrchnum.htm&r=1&f=G&l=50&s=8240313.PN.&OS=PN/8240313&RS=PN/8240313>.
- Hsu GL, Brock G, Martinez-Pineiro L, Nunes L, von Heyden B, Lue TF (1992) The three-dimensional structure of the tunica albuginea: anatomical and ultrastructural levels. *Int J Impot Res* 4:117–129.
- Hsu GL, Hsieh CH, Wen HS, Chen YC, Chen SC, Mok MS (2003) Penile venous anatomy: an additional description and its clinical implication. *J Androl* 24:921–927.
- Hsu GL, Lin CW, Hsieh CH, Hsieh JT, Chen SC, Kuo TF, Ling PY, Huang HM, Wang CJ, Tseng GF (2005) Distal ligament in human glans: a comparative study of penile architecture. *J Androl* 26:624–628.
- Hsu GL, Chen HS, Hsieh CH, Lee WY, Chen KL, Chang CH (2010a) Clinical experience of a refined penile venous surgery procedure for patients with erectile dysfunction: is it a viable option? *J Androl* 31:271–280.
- Hsu GL, Chen HS, Hsieh CH, Lee WY, Chen KL, Chang CH (2010b) Salvaging penile venous stripping surgery. *J Androl* 31:250–260.
- Hsu GL, Hung YP, Tsai MH, Hsieh CH, Chen HS, Molodysky E, Huynh CC, Yu HJ (2012) Penile veins are the principal

- component in erectile rigidity: a study of penile venous stripping on defrosted human cadavers. *J Androl* 33:1176–1185.
- Hsu GL, Zaid UX, Hsieh CH, Huang SJ (2013) Acupuncture assisted regional anesthesia for penile surgeries. *Transl Androl Urol* 2:291–300.
- Kaminetsky J (2008) Epidemiology and pathophysiology of male sexual dysfunction. *Int J Impot Res* 20:S3–S10.
- McKay D (2004) Nutrients and botanicals for erectile dysfunction: examining the evidence. *Altern Med Rev* 9:4–16.
- Melman A, Gingell JC (1999) The epidemiology and pathophysiology of erectile dysfunction. *J Urol* 161:5–11.
- Molodysky E, Liu SP, Huang SJ, Hsu GL (2013) Penile vascular surgery for treating erectile dysfunction: current role and future direction. *Arab J Urol* 11:254–266.
- Montague DK (2011) Penile prosthesis implantation in the era of medical treatment for erectile dysfunction. *Urol Clin North Am* 38:217–225.
- Montague DK, Jarow JP, Broderick GA, Dmochowski RR, Heaton JP, Lue TF, Milbank AJ, Nehra A, Sharlip ID (2005) Chapter 1: the management of erectile dysfunction: an AUA update. *J Urol* 174:230–239.
- Morrison H (2000) Sildenafil (Viagra): cardiac risks. *Can Med Assoc J* 163:86–91.
- Murphy LL, Lee TJ (2002) Ginseng sex behavior and nitric oxide. *Ann N Y Acad Sci* 962:372–377.
- Nachtsheim D (1998) Sildenafil: a milestone in the treatment of impotence. *West J Med* 169:112–113.
- Neychev VK, Mitev VI (2005) The aphrodisiac herb *Tribulus terrestris* does not influence androgen production in young men. *J Ethnopharmacol* 3:319–323.
- Polk HC Jr, Cheadle WG, Franklin GA (2001) Principles of operative surgery. In: Sabiston Textbook of Surgery. Townsend CM Jr (ed). WB Saunders, Philadelphia, pp 163–188.
- Sandroni P (2001) Aphrodisiacs past and present: a historical review. *Clin Auton Res* 11:303–307.
- Simmons MN, Jones JS (2007) Male genital morphology and function: an evolutionary perspective. *J Urol* 177:1625–1631.
- Tsai TC, Hsu GL, Chen SC, Wang CL (1988) Analysis of the results of reconstructive surgery for vasculogenic impotence. *J Formos Med Assoc* 87:182–187.
- Wen HS, Hsieh CH, Hsu GL, Kao YC, Ling PY, Huang HM, Wang CY, Einhorn EF (2005) The synergism of penile venous surgery and oral sildenafil in treating patients with erectile dysfunction. *Int J Androl* 28:297–303.
- Wooten JS (1902) Ligation of the dorsal vein of the penis as a cure for atonic impotence. *Texas Med J* 18:325–328.